

# “ New radiographic heart measurement to detect left atrial enlargement in dogs

## THE INVENTION

Left atrial roof measurement in cardiac X-ray is clinically effective to detect left atrial enlargement of the heart and later degenerative mitral valve diagnosis in dogs. We are seeking a company partner to commercialize it through a license agreement.

### Innovative aspects and advantages

> LA roof measurement shows higher sensitivity and specificity than current VHS measurement to detect left atrial enlargement in dogs

> A prospective and multicenter study in 10 healthy dogs and 24 dogs with DMVD disease shows LA roof measurement as the most clinically efficient way to distinguish between healthy dogs and unhealthy dogs in comparison to VHS and LABL

### IP Rights

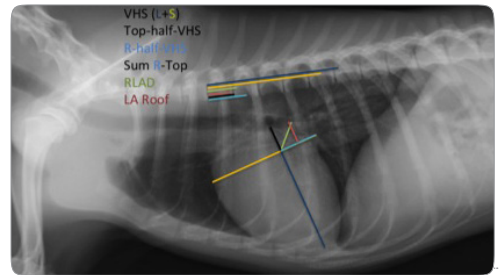
Priority Patent application, 11th June 2013

### Scientific Team

Professor David Prandi leads the scientific team specialized in radiology and surgery on cats and dogs belonging to the Department of Animal Medicine and Surgery of the UAB

## Summary

Degenerative mitral valve disease (DMVD) is the most frequent cardiac disease in dogs (75%) and subsequent mitral regurgitation causes left atrial enlargement (LAE). Currently, diagnostic imaging of mitral valve disease is done, mainly, by echocardiography. However, this technique is not widely available to general practitioners. The vertebral heart scale (VHS) is a radiographic measurement of global heart enlargement in dogs but is nonspecific for enlargement of individual heart chambers. Existing radiographic measurements such as the left atrial bisecting line (LABL) are clinically effective for detecting LAE, but can be difficult to accurately estimate the dorsal limit of the left atrium because the measurements can be obstructed by normal anatomical structures and perihilar pulmonary edema due to congestive heart failure. The new radiographic heart measurement, Left atrial roof (see figure 1) overcomes the current difficulties of VHS and LABL measurements to detect LAE. This measurement separately or jointly with R-Half-VHS, top-Half-VHS, and Sum R-Top measurements constitute the most efficient tool to minimize failure in LAE diagnosis in dogs.



► Fig 1. Thoracic X-ray image of a dog. LA roof measurement is marked in red (distance from midpoint of R-half-VHS to LA roof). R-half-VHS measurement is the distance from the intersection of the long (L) and short (S) axis of the heart to caudal heart limit. The top-half-VHS is the distance from the intersection of the L and S axis of the heart to the ventral border of carina. The sum of these measurements is the Sum R-Top.